

ARTICLE

# Envenomation by the asp caterpillar (*Megalopyge opercularis*)

DAVID M. EAGLEMAN

*Baylor College of Medicine, Department of Neuroscience, Houston, Texas, USA*

**Background.** The Asp Caterpillar, *Megalopyge opercularis*, is endemic to the southern United States and causes hundreds of human envenomations annually. Envenomation from the spines of the caterpillar causes severe pain, burning, swelling, nausea, abdominal distress, and headache. Despite the high prevalence of envenomations, little is known about the caterpillars, their geographical distribution, and the symptoms they engender. **Methods.** We collected and analyzed 188 case reports of asp caterpillar envenomations over a three-year period. **Results.** The geographical distribution of the caterpillars is confined to the southeast United States, largely in Texas, Louisiana, and Florida. Symptoms of envenomation vary, but typically include burning pain, swelling, nausea, and itching. The peak months of envenomation are July through November, with few cases reported at other times of year. **Discussion.** This study sheds light on the caterpillars' distribution and the range of symptoms caused in order to aid in diagnosing puss moth caterpillar envenomation.

**Keywords** Caterpillar; *Megalopyge Opercularis*; Asp caterpillar

## Introduction

The best known venomous caterpillar in the American southwest is the puss moth caterpillar, *Megalopyge opercularis*, commonly called an asp, wooly asp, Italian asp, opossum bug, wooly slug, and el perrito (1–5). It is considered one of the most toxic caterpillars in North America (6,7). The caterpillar is abundant and may infest shade trees and shrubbery around homes, schools, and in parks. They hold little importance as enemies of shade trees, but they present a real danger when coming in contact with people. When a puss moth caterpillar rubs against or is pressed against the skin, venomous hairs break off and embed themselves, causing a severe burning sensation and rash. Within hours a clear pattern of hemorrhagic papules will arise, usually lasting for several days; lymphadenopathy and swelling may develop (1–5,8–13).

Asp caterpillars resemble a teardrop-shaped tuft of cotton or fur. Their hairs are long and silky. Their color varies from white, gray, light tan, yellow, reddish-brown, or a mixture of colors (Fig. 1A–1C). The mature caterpillar is 1 to 1.5 inches long with seven pairs of prolegs (suction-cup-like claspers on the rear of the body). The head and legs are not visible from above. The hairs form a midline ridge along the back. Beneath the hairs are concealed tubercular ridges: rows of sharp, short, hollow spines (like porcupine quills) that penetrate skin and discharge venom upon contact. Each hollow spine is connected to a poison sac (1). In adulthood, the caterpillar

becomes a puss moth, which has blunt wings covered with long, wavy hair and a wingspan of 1 to 1.5 inches. The wings are orange at the base, fading to cream-colored at the tips.

Asp caterpillars pose a seasonal health hazard. Intense, throbbing pain develops immediately or within five minutes of contact with the caterpillar. Stings on the arm may also result in pain in the armpit region. Erythematous (blood-colored) spots typically appear at the site of the sting (Fig. 1D–1F). Other symptoms can include headaches, nausea, vomiting, intense abdominal distress, lymphadenopathy, lymphadenitis, and sometimes shock or respiratory stress (1,14,15). Pain usually subsides within an hour and spots disappear in a day or so; however, with a larger dose of the venom, it is not uncommon for the symptoms to last several days or longer.

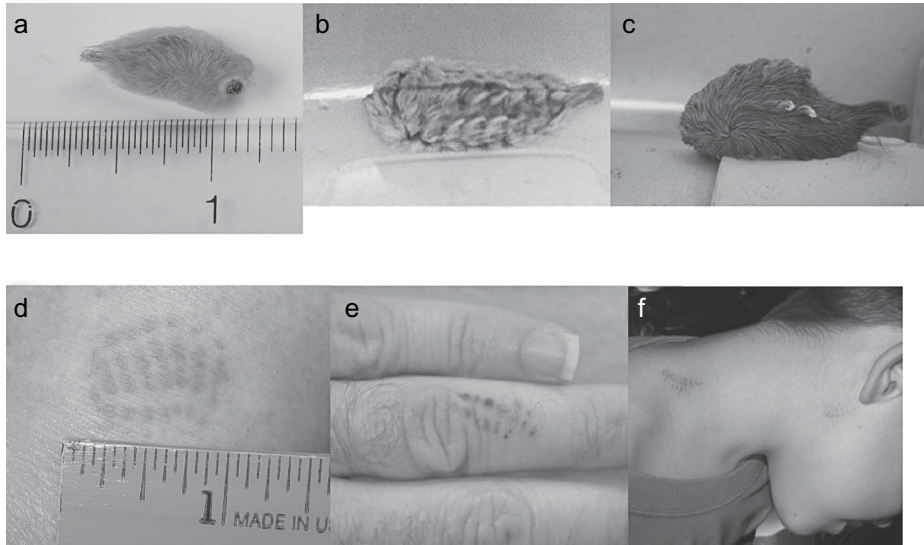
Often, those envenomated by the asp caterpillar find that health care professionals have never seen nor heard of the creature; the caregivers are left with little to go on, and the victims are left with the distress of an unknown prognosis. Existing literature often involves a single case study (15–17), a self-reported envenomation (1), or a handful of cases (18). The need for better information about these caterpillars is not purely academic: at times public schools in Texas have been temporarily shut down because of outbreaks of the caterpillar (1), and more generally the problem of ignorance in the medical community can lead to under-treatment or mistreatment.

## Methods

To address these problems, this study was engineered to determine the geographical distribution of these caterpillars,

Received 25 October 2006; accepted 18 January 2007.

Address correspondence to David M. Eagleman, Baylor College of Medicine, Department of Neuroscience, 1 Baylor Plaza Houston, Texas 77030, USA. E-mail: eagleman@bcm.edu



**Fig. 1.** (A-C) The Asp Caterpillar, *Megalopyge opercularis*, can vary in color from white to gray to brown, but is easily recognized by its fuzzy appearance and teardrop shape. (D-F) Encounters with asp caterpillars are unmistakably evidenced by a grid-like pattern of erythematous spots at the site of contact.

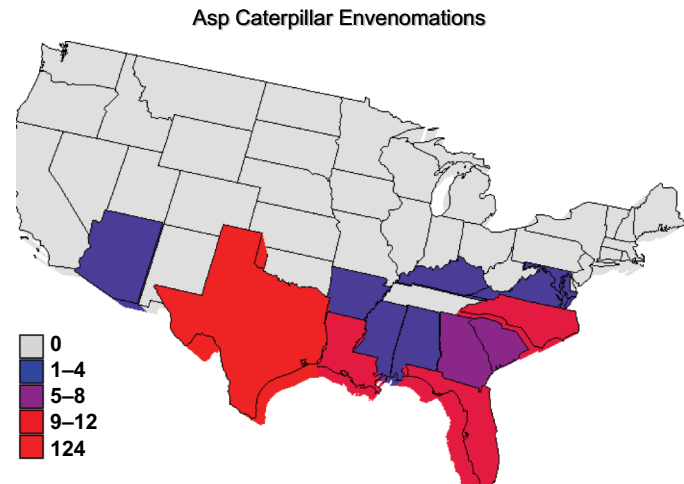
their season, and the spectrum of experienced symptoms. To this end, we constructed a laboratory website that contained information about the asp caterpillar (<http://eaglemanlab.net/asp>). On the website, we requested people who had been envenomated to e-mail the author of the website to describe the details of their location and symptoms. There were 188 cases reported (either by victims or their relatives) from October 2003 to October 2006.

We are aware that this method of data collection leaves open the possibility of response bias: those with the worst symptoms may be more prone to look for information on the Internet and e-mail the investigator of the study. Further, there may be a socio-economic response bias: those living in poor areas may not have access to the Internet. However, with these caveats in mind, we can nonetheless learn a great deal about the caterpillar's geographical distribution, the range of symptoms caused, and the seasons in which this occurs.

## Results

### *Geographical distribution*

Figure 2 shows the geographical distribution within the United States of cases reported through the author's website over a three-year period. Note the disproportionate number of reports from Texas ( $n=124$ ) as compared to the runner-ups, Florida and Louisiana, with 10 reports each. Normalizing by the land area of each state (Table 1), we find that Texas still leads, but with only twice as many reports per square mile as Louisiana, and two-and-a-half times that of Florida. Perhaps because the author's webpage has not yet been translated into



**Fig. 2.** Geographical distribution within the United States of cases reported over a three-year period. Colors reflect numbers of cases reported.

Spanish, no emails have been received from Mexico; thus, this report sheds no light on statistics south of the Rio Grande.

Note that collecting data over the Internet is a fast and effective way to generate a snapshot of geographic distribution; in previous generations this was accomplished more laboriously by travel and correspondence between experts. These earlier methods left gaps in our picture of the distribution; thus, the first reports of asp envenomation in Arkansas only appeared 30 years ago (16), and in Florida 20 years ago (18).

**Table 1.** Number of asp caterpillar envenomations reports by state (second column) and normalized by land area (fourth column)

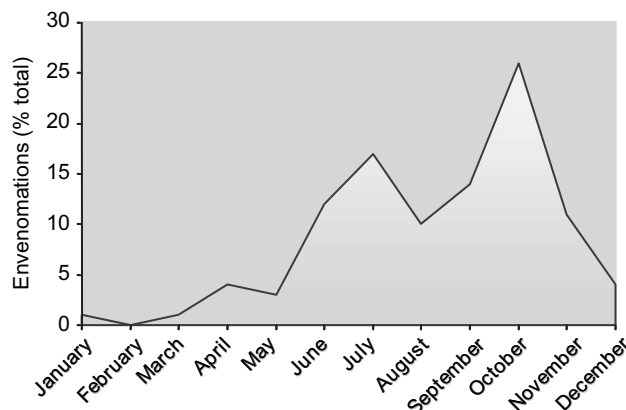
State	Reports	Land area	Normalized
AL	3	50767	0.12
AR	2	52078	0.08
AZ	1	113508	0.02
FL	10	54153	0.39
GA	4	58056	0.15
KY	1	39669	0.05
LA	10	44521	0.47
MD	1	9837	0.21
MS	2	47233	0.09
NC	8	48843	0.35
SC	4	30203	0.28
TX	124	262017	1.00
VA	2	39704	0.11

172 of the 188 total case reports included clear geographical information that could be used for this table.

### Season of the caterpillar

The caterpillars pass winter in cocoons on twigs. The moth emerges from the cocoon in late spring and deposits her eggs on shrubs and trees. Within days the eggs hatch, and whitish larvae emerge. The caterpillars tend to darken as they mature. The caterpillars feed on deciduous trees and shrubs (4).

To determine the time(s) of year when asp caterpillars pose the greatest risk, we analyzed envenomations by the month in which they occurred (Fig. 3). The double hump in the data is consistent with a report by Goddard (6) that the asp caterpillar has two generations a year, the first developing in spring/early summer and the second in the fall. Also consistent is Goddard's observation that they seem to be especially abundant from September to November (6).



**Fig. 3.** Asp caterpillar envenomations by month. n=163 of the 188 case reports which contained the month of envenomation in the description.

### Symptoms

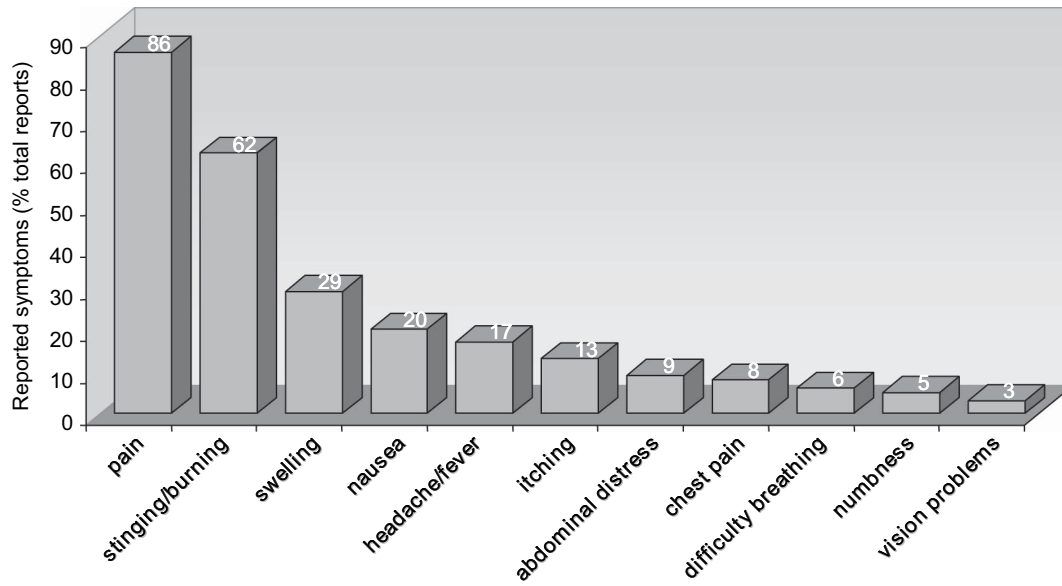
Although the possible symptoms of asp caterpillars envenomations have been previously reported, the statistics of those symptoms (i.e., how common they are across individuals) has remained unknown. Figure 4 shows the distribution of self-described symptoms from 159 of 188 subjects whose reports allowed such an analysis. Almost all victims described pain, with many describing more specifically stinging or burning. Typical reports included descriptions such as “it felt as though my arm had been broken”; “it immediately felt like a hammer hit me”; and “I have had kidney stones before, but I believe the pain I am experiencing from the asp sting is worse.” Twenty-nine percent described swelling of a limb, similar to the 28% reported by Stipetec et al. (9). Twenty percent or fewer felt nausea, headache/fever, and itching. Approximately 9% report acute abdominal distress (as has been reported before in Neustater et al. (17)), sometimes lasting for days.

Other complaints not represented in the categories in Figure 4 include welts, hives, or sweating at the site of the sting, and other scattered reports of symptoms such as muscle spasm, faintness, tingling, and a red streak on the skin from the sting site to the nearest lymph gland.

It is also reported in about a third of victims that the pain radiates. For example, a sting on the hand or forearm can radiate pain up the arm into the armpit and chest, leading some to spuriously believe they are having a heart attack. Similarly, if the sting site is on the leg, pain can radiate up the leg to “coalesce” in the testicle or inguinal canal. In a previous study, radiating pain and systemic effects were present in 35.2% of *M. opercularis* envenomations (5). In a study of phone calls to Central Texas Poison Control Center, 99% of patients experienced local pain at the site of the sting and 27% experienced “intense radiating pain” (9).

Not represented in this analysis is the feeling of panic that many sting victims reported to us. Because many people do not know that caterpillars can be venomous, or sometimes do not detect that they came into contact with a caterpillar, some victims find themselves in intense pain without an explanation. It is not unheard of that some victims are launched into panic attacks by the unexpected onset of the pain.

Since patient histories were volunteered, and individual follow-up was not always possible, there is a possible conflation of descriptions like “pain” and “burning,” which in some cases were used interchangeably, and in other cases were described as different symptoms (e.g., “the burning was accompanied by a terrible pain in my arm, as though my entire arm had been charlie horsed”). Since not all patients volunteered clear descriptions, the statistics in Figure 4 are compiled from those reports from which the appropriate data could be meaningfully extracted (n=159). As noted above, the severity of the symptoms may reflect a reporting bias, wherein only those with the worst symptoms volunteer their stories; nonetheless, this report is useful for demonstrating the range of symptoms.



**Fig. 4.** Frequency of symptoms reported. n=159 cases whose symptoms were described with enough detail or clarity to allow classification into the above categories.

Many victims report varying degrees of success with home remedies. One successful strategy consists of applying tape to the site and pulling it off to remove spines (“stripping”). Other victims report applying ice packs, oral antihistamine, baking soda, hydrocortisone cream, juice from the stems of comfrey plants, or calamine lotion. Other papers in the literature have suggested relief through intravenous calcium gluconate (17) or systemic corticosteroids (19). As noted by Stipetic et al. (9) and many of our case reports, most victims have a difficult time finding any treatment that promptly relieves pain.

As for what to do about local infestations of the Asp caterpillar, one patient reports success in killing the caterpillars with the pesticide Cypermethrin (Viper Insecticide Concentrate). It has also been suggested that *Bacillus thuringiensis* or plant oil products can cut down on asp caterpillar infestations (7).

## Discussion

This study reveals that the caterpillar *M. opercularis* covers a larger range of the United States than previously reported, spreading as far north as Virginia and Kentucky. This study only takes into account the distribution of the asp caterpillar in the United States; they are also known to be endemic to Central and South America (6).

There has been some problem diagnosing Asp caterpillar envenomation in the past because even health care providers who know of the caterpillar are not aware of the potential range of the symptoms. Symptoms such as nausea, severe abdominal distress, and chest pain often confuse the clinical picture in the emergency room, because clinicians are

unaware that these symptoms are commonly a part of the constellation. More generally, many patients report that neither they nor their health care providers had any knowledge at all of these toxic creatures. The high prevalence of caterpillar envenomations thus calls for more study and understanding of these arthropods. This study sheds light on their distribution, seasons and range of symptoms in order to aid in diagnosing puss moth caterpillar envenomation. Future studies will be required to expose the details of their venom with the goal of providing an antidote.

## References

1. Foot NC. Pathology of the dermatitis caused by *Megalopyge opercularis*, a Texan caterpillar. *Journal of Experimental Medicine* 1922; 35:737–753.
2. Bishopp FC. The puss caterpillar and the effects of its sting on man. Washington, DC: US Dept of Agriculture Department Circular, 1922, vol. 288:1–14.
3. Micks DW. Clinical effects of the sting of the “puss caterpillar” (*Megalopyge opercularis*) on man. *Tex Rep Biol Med* 1952; 10:399–405.
4. McGovern JP, Barkin GD, McElhenney TR, Wende R. *Megalopyge opercularis*: Observations of its life history, natural history of its sting in man, and report of an epidemic. *JAMA* 1961; 175:1155–1158.
5. McMillan CW, Purcell WR. Hazards to health. The puss caterpillar, alias woolly slug. *N Engl J Med* 1964; 271:147–149.
6. Goddard J. *Physician’s guide to arthropods of medical importance*. CRC Press, 2002.
7. Garrett H. *Dear dirt doctor: Questions answered the natural way*. Austin: University of Texas Press, 2003.
8. Everson GW, Chapin JB, Normann SA. Caterpillar envenomations: A prospective study of 112 cases. *Vet Hum Toxicol* 1990; 32:114–119.
9. Stipetic ME, Rosen PB, Borys DJ. A retrospective analysis of 96 “asp” (*Megalopyge opercularis*) envenomations in Central Texas during 1996. *J Toxicol Clin Toxicol* 1999; 37:457–462.

10. Erickson T, Ahrens WR, Aks S, Baum C, Ling L. Pediatric toxicology: Diagnosis and management of the poisoned child. New York: McGraw-Hill Professional, 2004.
11. Demain JG. Papular urticaria and things that bite in the night. *Curr Allergy Asthma Rep* 2003; 3:291–303.
12. Leshner JL, ed. An atlas of microbiology of the skin. New York: Taylor & Francis, 2000.
13. Weiss, E. Wilderness 911: A step by step guide for medical emergencies and improvised care in the backcountry. Seattle, WA: The Mountaineers Books, 1998.
14. Pesce H, Delgado A. Poisoning from adult moths and caterpillars. In venomous animals and their venoms, W. Bucherl and E. Buckley, eds. New York: Academic Press, 1971:119–156.
15. Pinson RT, Morgan JA. Envenomation by the puss caterpillar (*Megalopyge opercularis*). *Ann Emerg Med* 1991; 20:562–564.
16. Daly JJ, Derrick BL. Puss caterpillar sting in Arkansas. *Southern Medical Journal* 1975; 68(7):893–894.
17. Neustater BR, Stollman NH, Manten HD. Sting of the puss caterpillar: An unusual cause of acute abdominal pain. *Southern Medical Journal* 1996; 89(8):826–827.
18. el-Mallakh RS, Baumgartner DL, Fares N. Sting of puss caterpillar, *Megalopyge opercularis* (Lepidoptera: Megalopygidae): First report of cases from Florida and review of literature. *Journal of the Florida Medical Association* 1986; 73:521–525.
19. Rosen T. Caterpillar dermatitis. *Dermatologic Clinics* 1990; 8(2):245–252.